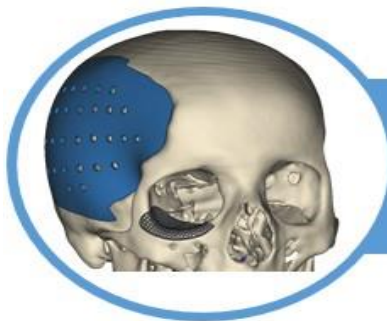

## ***Visualizing arteriosclerosis in dental radiographic shots: case report and literature review.***

John Lewis Clarson (1)

### LITERATURE REVIEW

#### Abstract

Dentists are trained to identify atheromatous plaques of the intimal layer of the common carotid artery on panoramic radiographs, but are less familiar with medial layer arteriosclerosis, which results in “pipe-stem” calcifications that may present on intraoral as well as extraoral dental radiographs. Medial arteriosclerosis is often found in diabetics and patients with chronic kidney disease, and is a strong predictor of stroke and cardiovascular events. Two case reports are presented that illustrate the presentation of medial arteriosclerosis in facial and maxillary arteries on dental radiographs. Dentists can play an important role in identifying patients at risk for stroke and cardiovascular events.

**Keywords:** *Facial artery, vascular calcification, arteriosclerosis, dental radiography.*

## Visualizando as arterioscleroses nas tomadas radiográficas dentárias: relato de caso e revisão de literatura.

### Resumo

Os dentistas são treinados para identificar placas de ateroma da camada íntima da artéria carótida comum em radiografias panorâmicas, mas estão menos familiarizados com a arteriosclerose da camada média, que resulta em calcificações em "haste de tubo" que podem se apresentar tanto em radiografias dentárias intraorais quanto extraorais. A arteriosclerose medial é freqüentemente encontrada em diabéticos e pacientes com doença renal crônica e é um forte preditor de acidente vascular cerebral e eventos cardiovasculares. São apresentados dois relatos de casos que ilustram a apresentação da arteriosclerose medial nas artérias facial e maxilar nas radiografias dentárias. Os dentistas podem desempenhar um papel importante na identificação de pacientes em risco de acidente vascular cerebral e eventos cardiovasculares.

**Palavras Chave:** *Artéria facial, calcificação vascular, arteriosclerose, radiografia dentária*

**Instituição afiliada:** 1- Dentist professor at York Dental School .

**Dados da publicação:** *Artigo recebido em 10 de Janeiro, revisado em 13 de Janeiro, aceito para publicação em 20 de Janeiro e publicado em 29 de Janeiro.*

**DOI:** <https://doi.org/10.36557/2674-8169.2020v3n1p36-48>



John Lewis Clarson [jlew79@gmail.com](mailto:jlew79@gmail.com)



This work is licensed under a [Creative Commons Attribution 4.0 International License](https://creativecommons.org/licenses/by/4.0/).

## INTRODUCTION

Dentists can help with identifying vascular calcifications that are markers for cardiovascular events [1, 2]. Dentists are trained in the identification of atheromatous plaques of the common carotid artery on panoramic radiography. Atherosclerosis is characterized by lipid accumulation, inflammation, fibrosis, plaque formation and calcification in the intimal layer of arteries that ultimately can obstruct the lumen of vessels or release emboli [3]. Common carotid artery calcifications detected on panoramic radiography have been shown to be powerful markers for future cardiovascular and cerebrovascular events [1, 2, 4]. They appear as circular or irregular radiopacities posterior to the angle of the mandible in the soft tissues of the neck, and their prevalence on panoramic radiography ranges from 6.9% in the general population to as high as 33.8% in patients with systemic diseases, such as Type 2 diabetes mellitus, hypertension, and hyperlipidemia [5-10].

There is another type of vascular calcification, medial artery calcification also known as Mönckeberg arteriosclerosis, that leads to a non-obstructive stiffening in the medial layer of arteries and decreased compliance of blood vessels [11]. The loss of arterial elasticity may lead to derangement in blood flow and injury to the endothelium, thus increasing the risk of thrombosis. As with intimal atherosclerosis, medial arteriosclerosis is associated with cardiovascular morbidity and mortality [11-13]. Medial artery calcification is related to age and structural changes from metabolic disease, such as diabetes and chronic kidney disease, and is independent of hypercholesterolemia [14, 15]. Medial artery sclerosis most often occurs in the extremities, but can also occur in the abdomen and head and neck areas [16, 17]. Dentists can assist in the detection of this type of vascular calcification, as arteriosclerosis of the facial artery can present in routine dental radiographs [16, 18-20].

### **Case Report 1**

A 75-year old white male presented to the Massachusetts General Hospital Dental Group for an initial outpatient comprehensive examination. His medical history was significant for the development of Type 1 diabetes mellitus at the age of 26 with resultant complications of peripheral vascular disease, peripheral neuropathy, autonomic neuropathy, retinopathy, toe amputation, and renal failure. He had poor chronic control and refused dialysis. He received a deceased donor left kidney and pancreas transplant at the age of 55. After the pancreatic transplant began to fail 13 years later, the patient was restarted on insulin. A repeat left kidney transplant was required at the age of 71.

The patient also had hypertension and hyperlipidemia, and a history of metabolic acidosis, deep vein thrombosis, and right leg angioplasty. He had no history of coronary artery disease, valvular disease, congestive heart failure, or arrhythmia. His medications included prednisone, tacrolimus, mycophenolate, insulin, furosemide, aspirin, and atorvastatin.

Clinical examination and a full mouth series of radiographs revealed that the patient had partial edentulism and mild periodontitis. The radiographic exam was also significant for “pipe-stem” radiopacities following a tortuous track visible on bilateral bitewing and mandibular posterior periapical views (Figure 1)

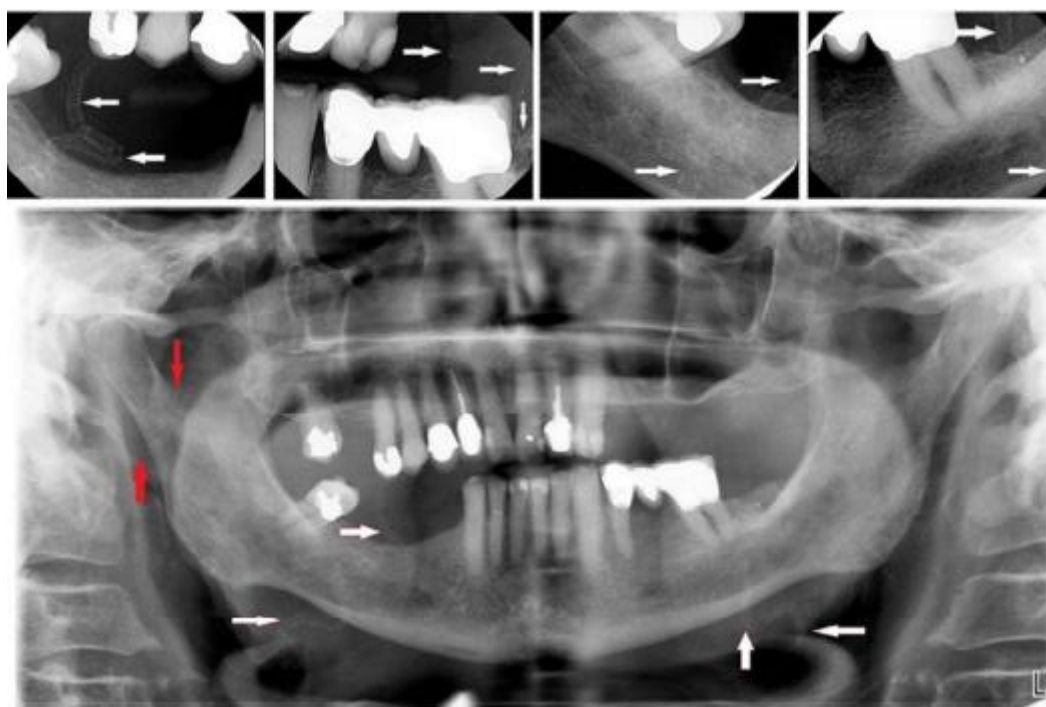


Figure 1. Case 1 - current bitewing, periapical, and panoramic radiographs revealing calcified bilateral facial (white arrows) and right maxillary (red arrows) arteries.

A panoramic radiograph was taken to better visualize the bilateral vascular calcification of the facial arteries (Figure 1). The panoramic radiograph also revealed a calcified right maxillary artery. Facial artery radiopacities were also evident to a lesser degree on bitewing radiographs from 5 years previously (Figure 2) and to an even lesser degree on bitewing and periapical views from a full mouth series taken 9 years previously (Figure 3).

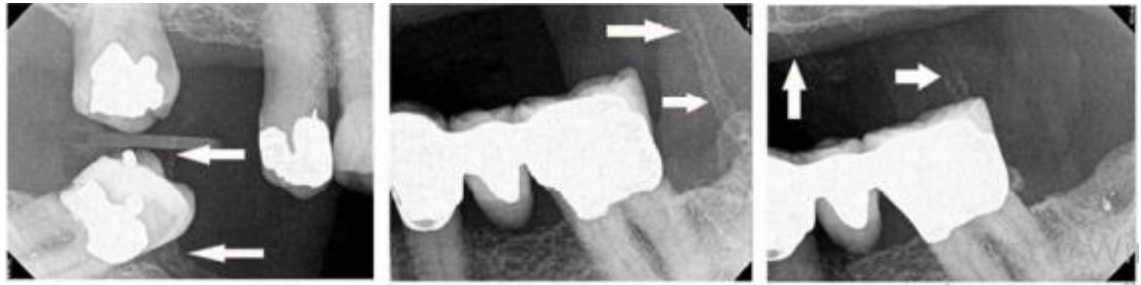


Figure 2. Case 1 – bitewing radiographs from 5 years previously revealing calcified bilateral facial arteries.

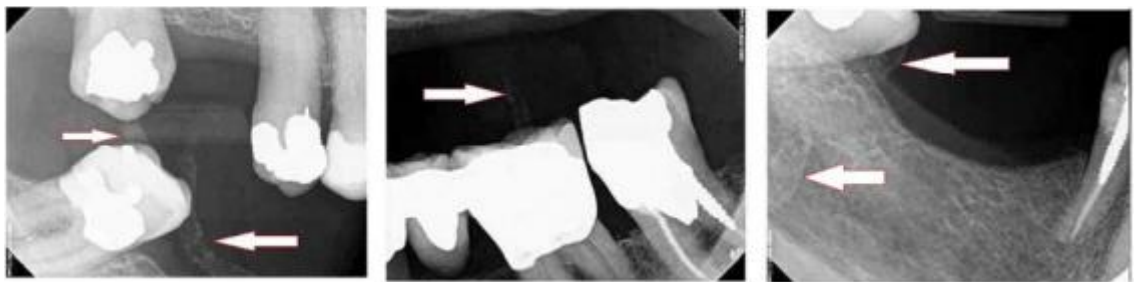


Figure 3. Case 1 – bitewing and periapical radiographs from 9 years previously revealing calcified bilateral facial arteries.

The patient's primary care physician, nephrologist, and cardiologist were informed of the dental radiographic findings of progressive calcification of bilateral facial arteries. The patient was to return for routine dental treatment.

## Case Report 2

A 29-year old male was admitted to the Massachusetts General Hospital for management of methicillin-sensitive *Staphylococcus aureus* bacteremia with a history of orthotopic liver transplant at 4 years of age for fulminant liver failure of unknown etiology, complicated by chronic rejection and tacrolimus-induced end-stage renal disease for the last 2 years. Other chronic conditions included hypertension and osteoarthritis. His medications included tacrolimus, prednisone, mycophenolate, sevelamer carbonate, amlodipine, lisinopril, valganciclovir, and vancomycin. He was on hemodialysis 3 days a week for the past year and was placed on the renal transplant waiting list. The current methicillin-sensitive *Staphylococcus aureus* infection was suspected to be from his hemodialysis line access, and a dental consultation was requested to rule out an oral source of infection.

On bedside examination, there was no extraoral asymmetry, lymphadenopathy, or limited range of motion. Intraoral examination revealed mild gingivitis and an MOD Ellis Class II fracture of the mandibular left second molar. A panoramic radiograph taken during admission revealed bilateral “pipe-stem” radiopacities following the tortuous tracks of the facial and maxillary arteries (Figure 4).

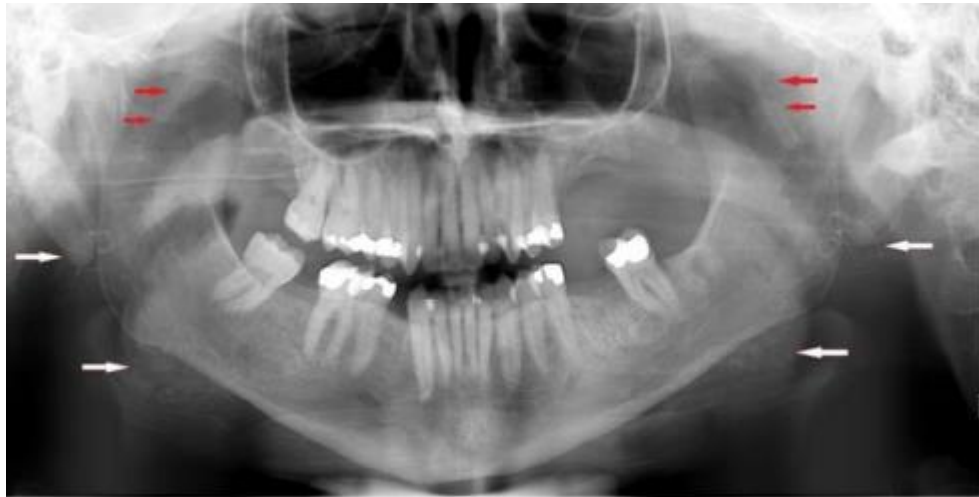

Figure 4. Case 2 – current panoramic radiograph revealing calcified bilateral facial (white arrows) and maxillary (red arrows) arteries.

The patient’s medical team was informed of the lack of oral source of infection as well as the presence of calcification of the maxillary and facial arteries.

## DISCUSSION

These two cases illustrate medial artery calcification in the head and neck area in patients with chronic kidney disease. People with chronic kidney disease have multiple risk factors that induce vascular smooth muscle cells to transform into chondrocyte- or osteoblast-like cells, including abnormal bone metabolism that leads to high levels of circulating calcium and phosphorous, low levels of calcification inhibitors, impaired renal excretion, and side effects of therapies to treat renal osteodystrophy that accelerate arterial calcification [11, 21, 22]. Medial artery calcification was first described as ring-like calcifications in a “pipe-stem” appearance by Lindblom in 1950 [23]. Medial artery calcifications detected by plain film have been reported in femoral, popliteal, anterior and posterior tibial, radial, and metacarpal arteries [19, 24]. Cases of facial artery medial calcification detected on intraoral radiographs were first published in 1942 by Ennis and 1966 by Hays [16, 18].

Tahmasbi-Arashlow reported a case of 65-year old male with diabetes mellitus and end-stage renal disease on hemodialysis with panoramic and intraoral radiographic evidence of facial artery and lingual artery medial calcification [17]. From a review of 2,422 panoramic radiographs taken on Veterans Administration patients, 6 cases of facial artery calcification were found (0.25% occurrence) by Miles with 4 of the 6 veterans having chronic renal failure, 2 of the 6 being on hemodialysis, and the age range of the 6 patients being 58-66 years [19]. Suarez reported a case of a 49-year old male with end-stage renal disease, cardiovascular disease, hyperparathyroidism, and renal osteodystrophy, whose panoramic radiograph revealed incidental findings of medial calcification of the facial, maxillary, and lingual arteries [20]. MacDonald reported a case of a 64-year old male with hypercalcemia and hyperphosphatemia from kidney disease, whose CT scan revealed medial calcification of not only the facial artery, but also the external carotid, lingual, internal maxillary, transverse facial, and superficial temporal arteries [25]. The patient profile of Case 1 in this report is typical in terms of age and medical issues, but the patient in Case 2 is unusual with respect to his young age, and to the best of this author's knowledge is the only published case of head and neck medial arteriosclerosis in a person in his twenties.

The common thread in most of these cases is chronic renal disease. Vipattawat determined that vascular calcification of any type can be detected on plain films in 57-81% of endstage renal disease patients and on CT scans in 60-70% of kidney transplant patients [22]. The prevalence of medial artery sclerosis in the general population was found to be 13.3% in males and 6.9% in females [24, 26].

Among populations at risk, medial artery calcification was found in 41.5% of Type 2 diabetics and 39.5% of end-stage renal disease patients [11]. With 9.4% of the U.S. population diagnosed with diabetes and 14% of the population diagnosed with chronic kidney disease, the prevalence of medial artery calcification is significant [27, 28].

Cardiovascular disease contributed to more than half of all deaths of patients with end-stage renal disease, and it has been shown that both intimal calcification and medial calcification of peripheral arteries are associated with increased mortality in these patients [13, 28]. Cardiovascular disease is also the leading cause of death in kidney transplant patients, accounting for 36-55% of deaths in patients with a functioning graft [29]. In kidney transplant patients the severity of vascular calcification increases with vintage of the transplant despite improvement in renal function and mineral metabolism [22]. Vascular calcification is a stronger predictor of cardiovascular events and all-cause mortality in kidney transplant patients than other risk factors [29].



Morbidity is also increased as affected arteries may not demonstrate a pulse. As a result, medial artery calcification is a significant risk factor for amputation in patients with chronic kidney disease and diabetes [30]. Diabetes and hypertension are the main causes of chronic kidney disease with almost half of chronic kidney disease patients having diabetes and/or cardiovascular disease [28]. Medial artery calcifications are not only observed in patients with advanced systemic disease. It has been shown that medial artery calcification in newly diagnosed non-insulin dependent diabetic patients is the most powerful predictive marker of future cardiovascular mortality even after adjustment for cardiovascular risk factors [31].

Therefore, recognition of medial artery calcification requires the institution of preventive measures and vigorous treatment where possible [11]. Dentists, and especially those working in medical settings where patients with significant health issues seek care, can play an important role in identifying patients at risk for cardiovascular events. Dentists are educated in identifying atheromatous plaques of the common carotid artery, but should also be aware of the presentation of medial arteriosclerosis in dental radiographs. They should know which populations are at high risk, but also understand that some patients who are much younger, as in Case 2, may present with advanced arteriosclerosis, and upon identification of such lesions make appropriate medical referrals [4, 20, 32].

## CONCLUSION

Vascular calcifications are associated with cardiovascular morbidity and mortality. It is important for dentists to be aware of dental radiographic evidence of medial arteriosclerosis in the patient population in general, and especially in patients at high risk, such as diabetics, patients with chronic renal disease, and renal transplant patients. Intraoral radiographs are taken every day in dental practice, allowing dentists to have a role in early detection of vascular calcification. Notification of medical providers and appropriate follow up may decrease the risks and complications of stroke and cardiovascular disease.

## THE AUTHORS DECLARE NO CONFLICTS OF INTEREST

This article is a literal copy of the article "Agnes Lau, Arteriosclerosis in Dental Radiographs: Two Case Reports, International Journal of Dental Medicine. Vol. 5, No. 1, 2019, pp. 14-18." This copy follows the CCBY precepts



<https://creativecommons.org/licenses/by/4.0/> , provided by the journal responsible for the original publication. There were changes in the title and authorship [33].

## REFERENCES

- [1] M. Moshfeghi, J. B. Taheri, N. Bahemmat, M. E. Evazzadeh, and H. Hadian. Relationship between carotid artery calcification detected in dental panoramic images and hypertension and myocardial infarction. *Iran J Radiol* 2014 Aug; 11(3):e8714. doi: 10.5812/iranjradiol.8714. Epub 2014 Aug 1.
- [2] A. H. Friedlander, S. M. El Saden, R. C. Hazboun, T. I. Chang, W. K. Wong, and N. R. Garrett. Detection of carotid artery calcification on the panoramic images of postmenopausal females is significantly associated with severe abdominal aortic calcification: a risk indicator of future adverse vascular events. *Dentomaxillofac Radiol*. 2015;44(7):20150094. doi: 10.1259/dmfr.20150094. Epub 2015 May 6.
- [3] M. Rogers, C. Goettsch, and E. Aikawa. Medial and intimal calcification in chronic kidney disease: stressing the contributions. *J Am Heart Assoc* 2013;2:e000481. doi: 10.1161/JAHA.113.000481.
- [4] J. Griniatsos, S. Damaskos, N. Tsekouras, C. Klonaris, and S. Georgopoulos. Correlation of calcified carotid plaques detected by panoramic radiograph with risk factors for stroke development. *Oral Surg Oral Med Oral Pathol Oral Radiol Endod* 2009; 108: 600-603.
- [5] J. R. Goncalves, J. L. Yamada, C. Berrocal, F. H. Westphalen, A. Franco, and A. Fernandes. Prevalence of pathologic findings in panoramic radiographs: calcified carotid artery atheroma. *Acta Stomatol Croat*. 2016 Sept;50(3):230-234.
- [6] U. K. Lee, T. I. Chang, N. Garrett, and A. H. Friedlander. Males with rheumatoid arthritis often evidence carotid atheromas on panoramic imaging: a risk indicator of future cardiovascular events. *J Oral Maxillofac Surg*. 2018 Jul;76(7):1447-1453. doi: 10.1016/j.joms.2018.01.006. Epub 2018 Jan 16.
- [7] Y. Atalay, F. Asutay, K. S. Agacayak, M. Koparal, F. Adali, and B. Gulsun. Evaluation of calcified atheroma on panoramic radiographs and Doppler ultrasonography in an older population. *Clin Interv Aging*. 2015 Jul 8;10:1121-1129. doi: 10.2147/CIA.S84683. eCollection 2015.
- [8] N. Gustafsson, J. B. Ahlqvist, U. Näslund, P. Wester, K. Buhlin, A. Gustafsson, and E. Levring Jäghagen. Calcified carotid artery atheromas in panoramic radiographs are associated with a first myocardial infarction: a case-control study. *Oral Surg Oral Med Oral Pathol Oral Radiol*. 2018 Feb;125(2):199-204.e1. doi: 10.1016/j.oooo.2017.10.009. Epub 2017 Nov 15.

- [9] N. Aghazadehsanai, T. I. Chang, N. R. Garrett, and A. H. Friedlander. Prevalence of calcified carotid artery atheromas on digital panoramic images among perimenopausal and postmenopausal African American women. *Oral Surg Oral Med Oral Pathol Oral Radiol.* 2017 May;123(5):621-625. doi: 10.1016/j.oooo.2017.01.011. Epub 2017 Feb 6.
- [10] N. Alves, N. F. Deana, and I. Garay. Detection of common carotid artery calcifications on panoramic radiographs: prevalence and reliability. *Int J Clin Exp Med* 2014; 7(8): 1931-1939.
- [11] P. Lanzer, M. Boehm, V. Sorribas, M. Thiriet, J. Janzen, T. Zeller, C. St. Hilaire, and C. Shanahan. Medial vascular calcification revisited: review and perspectives. *Eur Heart J.* 2014;35(23):1515-1525. doi: 10.1093/eurheartj/ehu163. Epub 2014 Apr 16.
- [12] K. J. Rocha-Singh, T. Zeller, and M. R. Jaff. Peripheral arterial calcification: prevalence, mechanism, detection, and clinical implications. *Catheter Cardiovasc Interv.* 2014 May 1;83(6):E212-E220. doi: 10.1002/ccd.25387. Epub 2014 Feb 10.
- [13] G. M. London, A. P. Guerin, S. J. Marchais, F. Metivier, B. Pannier, and H. Adda. Arterial media calcification in end-stage renal disease: impact on all-cause and cardiovascular mortality. *Nephrol Dial Transplant* 2003;18:1731-1740.
- [14] N. Abou-Hassan, E. Tantisattamo, E. T. D'Orsi, and W. C. O'Neill. The clinical significance of medial arterial calcification in end-stage renal disease in women. *Kidney Int.* 2015 Jan;87(1):195-199. doi: 10.1038/ki.2014.187. Epub 2014 May 28.
- [15] M. Rogers, C. Goettsch, and E. Aikawa. Medial and intimal calcification in chronic kidney disease: stressing the contributions. *J Am Heart Assoc* 2013;2:e000481. doi: 10.1161/JAHA.113.000481.
- [16] J. B. Hays, J. A. Gibilisco, and J. L. Juergens. Calcification of vessels in cheek of patient with medial arteriosclerosis. *Oral Surg* 1966;24:299-302.
- [17] M. Tahmasbi-Arashlow, S. Barghan, D. Kashtwari, and M. K. Nair. Radiographic manifestations of Mönckeberg arteriosclerosis in the head and neck region. *Imaging Sci Dent* 2016; 46;53-56.
- [18] L. M. Ennis and L. W. Burket. Calcified vessels of the cheeks: demonstration by means of dental roentgenograms. *Ann Dent* 1942;1:111-113.
- [19] D. A. Miles and R. M. Craig. The calcified facial artery: a report of the panoramic radiographic incidence and appearance. *Oral Surg Oral Med Oral Pathol* 1983;55:214-219.
- [20] M. M. Suarez-Cunqueiro, J. Duker, N. Leibehenschel, R. Schön, and R. Schmelzeisen. Calcification of the branches of the external carotid artery detected by panoramic radiography: a case report. *Oral Surg Oral Med Oral Pathol Radiol Endod* 2002;94:636-640.

- [21] K. Nitta and T. Ogawa. Vascular calcification in end-stage renal disease patients. *Contrib Nephrol.* 2015;185:156-167. doi: 10.1159/000380980. Epub 2015 May 19.
- [22] K. Vipattawat, C. Kitiyakara, B. Phakdeekitcharoen, S. Kantachuvesiri, V. Sumethkul, S. Jirasiritham, W. Stitchantrakul, and S. Disthabanchong. Vascular calcification in long-term kidney transplantation. *Nephrology* 2014;19:251- 256.
- [23] A. Lindblom. Arteriosclerosis and arterial thrombosis in the lower limb. A roentgenological study. *Acta Radiol.* 1950;80(Suppl.):1-80.
- [24] K. Kröger, A. Stang, J. Kondratieva, S. Moebus, E. Beck, A. Schmermund, S. Möhlenkamp, N. Dragano, J. Siegrist, K. Jöckel, and R. Erbel. Prevalence of peripheral arterial disease – results of the Heinz Nixdorf recall study. *Eur J Epidemiol* 2006;21:279-285.
- [25] D. S. MacDonald, L. Zhang, and Y. Gu. Calcification of the external carotid arteries and their branches. *Dentomaxillofacial Radiology* 2012;41:615-618.
- [26] R. G. Micheletti, G. A. Fishbein, J. S. Curren, and M. C. Fishbein. Mönckeberg sclerosis revisited: a clarification of the histologic definition of Mönckeberg sclerosis. *Arch Pathol Lab Med* 2008;132:43-47.
- [27] Centers for Disease Control and Prevention. National Diabetes Statistics Report, 2017. Atlanta, GA: Centers for Disease Control and Prevention, U.S. Dept of Health and Human Services; 2017.
- [28] Kidney Disease Statistics for the United States (December 2016). Retrieved from <https://www.niddk.nih.gov/healthinformation/health-statistics/kidney-disease>. Accessed March 24, 2018.
- [29] G. Cianciolo, I. Capelli, M. L. Angelini, C. Valentini, O. Baraldi, M. P. Scolari, and S. Stefoni. Importance of vascular calcification in kidney transplant recipients. *Am J Nephrol* 2014;39:418-426.
- [30] R. C. Johnson, J. A. Leopold, and J. Loscalzo. Vascular calcification: pathobiological mechanisms and clinical implications. *Circ Res* 2006;99:1044-1059.
- [31] L. Niskanen, M. Suhonen, O. Siitonen, and M. Uusitupa. Medial artery calcification predicts cardiovascular mortality in NIDDM. *Diabetes Care* 1994;17:1-5.
- [32] I. A. Monteiro, C. Ibrahim, R. Albuquerque, N. Donaldson, F. Salazar, and L. Monteiro. Assessment of carotid calcifications on digital panoramic radiographs: retrospective analysis and review of the literature. *J Stomatol Oral Maxillofac Surg.* 2018 Apr;119(2):102-106. doi: 10.1016/j.jormas.2017.11.009. Epub 2017 Nov 20.
- [33] Agnes Lau, Arteriosclerosis in Dental Radiographs: Two Case Reports, *International Journal of Dental Medicine*. Vol. 5, No. 1, 2019, pp. 14-18. doi: 10.11648/j.ijdm.20190501.13